

Recognition and Rehabilitation of Common Musculoskeletal Problems in Primary Care

Edward Shahady MD

Clinical Professor Family Medicine


**University of Miami and University of
Florida**

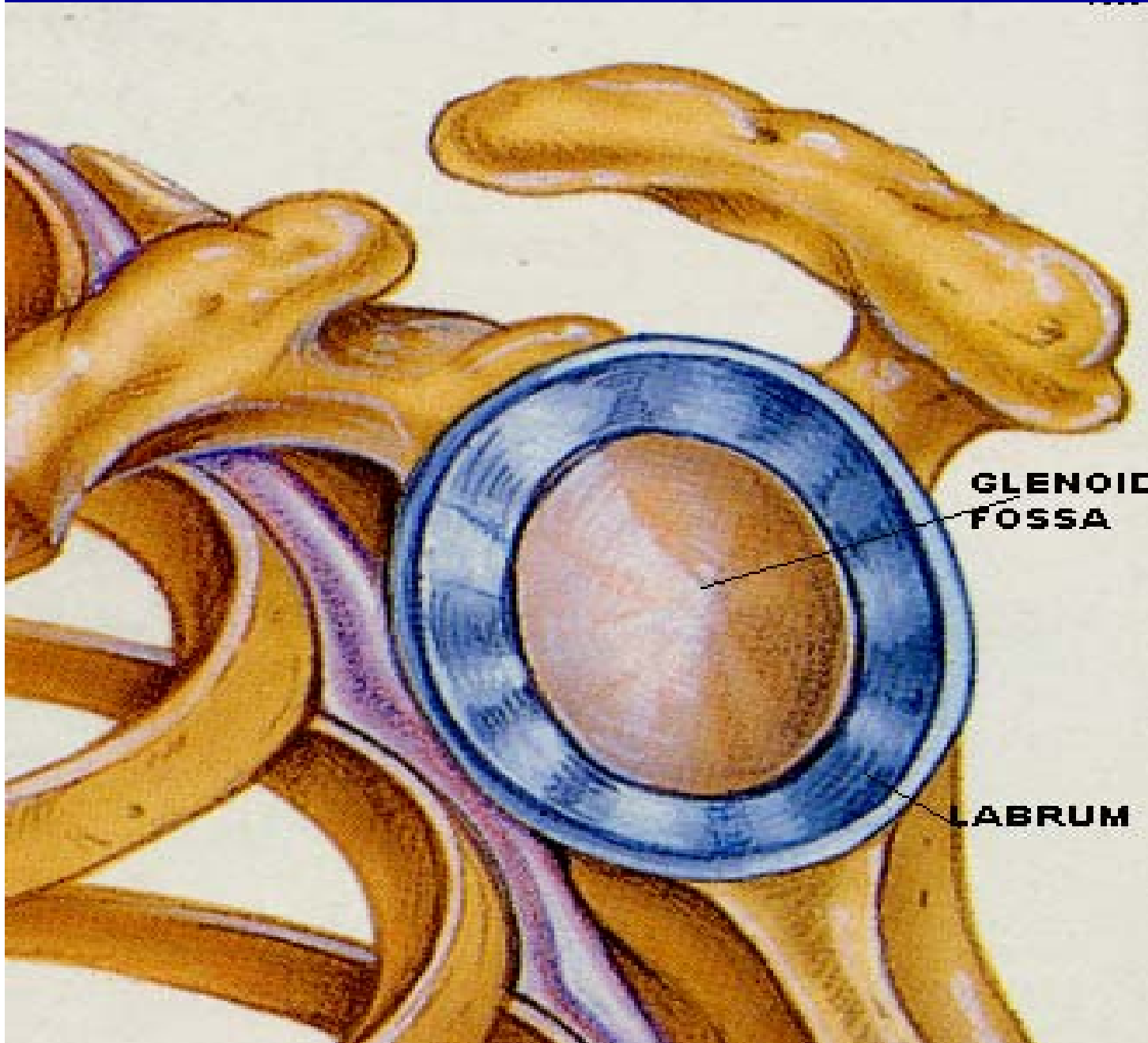
Goals of Presentation

- Present cases of some common MS problems seen in primary care
- Discuss how knowledge of anatomy and physical exam make treatment for these common problems more effective
- Laugh and have some **Fun**

Edward J. Shahady *Editor*

Primary Care of Musculoskeletal Problems in the Outpatient Setting





**Glenoid
provides
glide for
humeral
head**

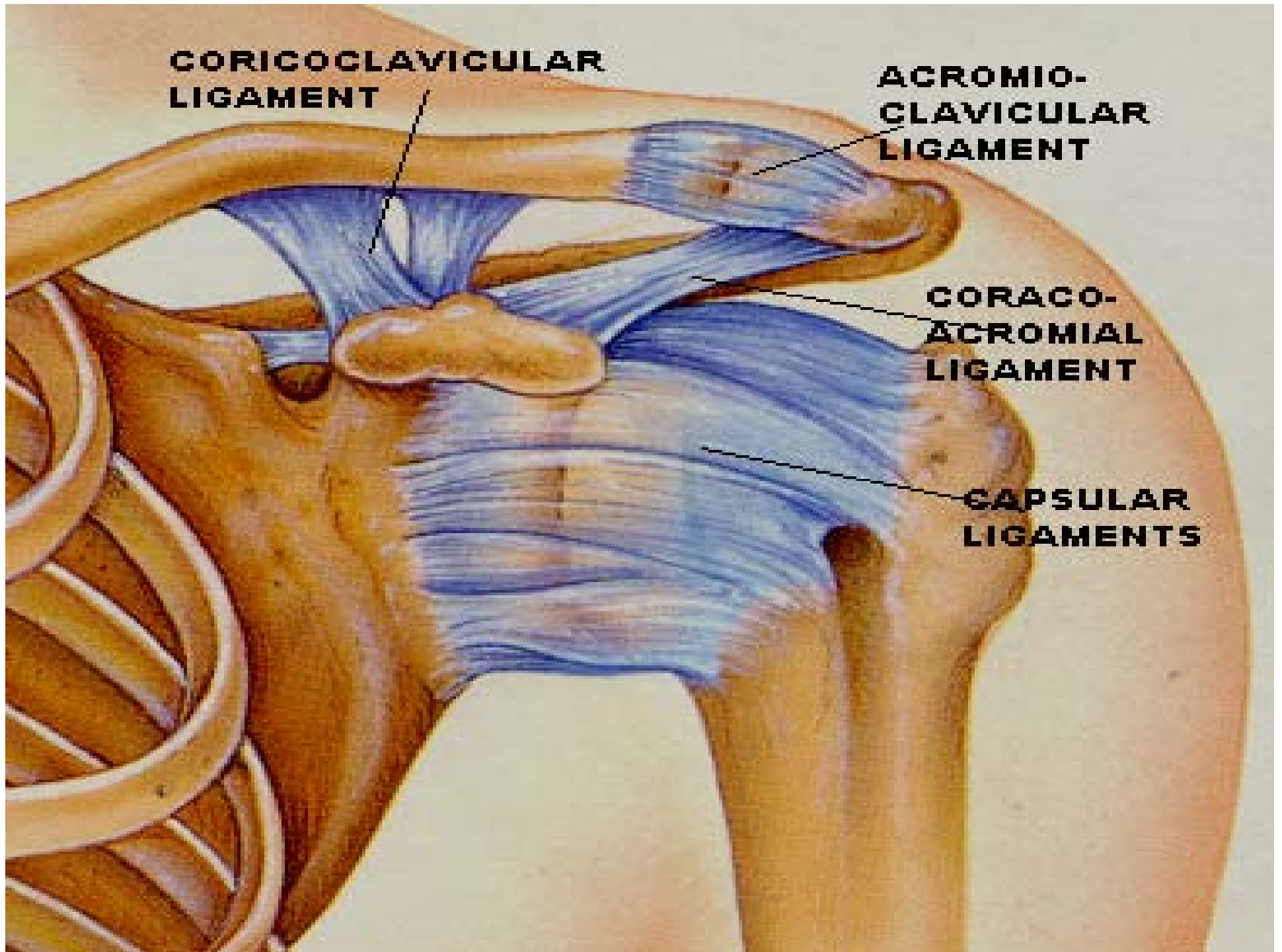
**Basketball
on
a plate**

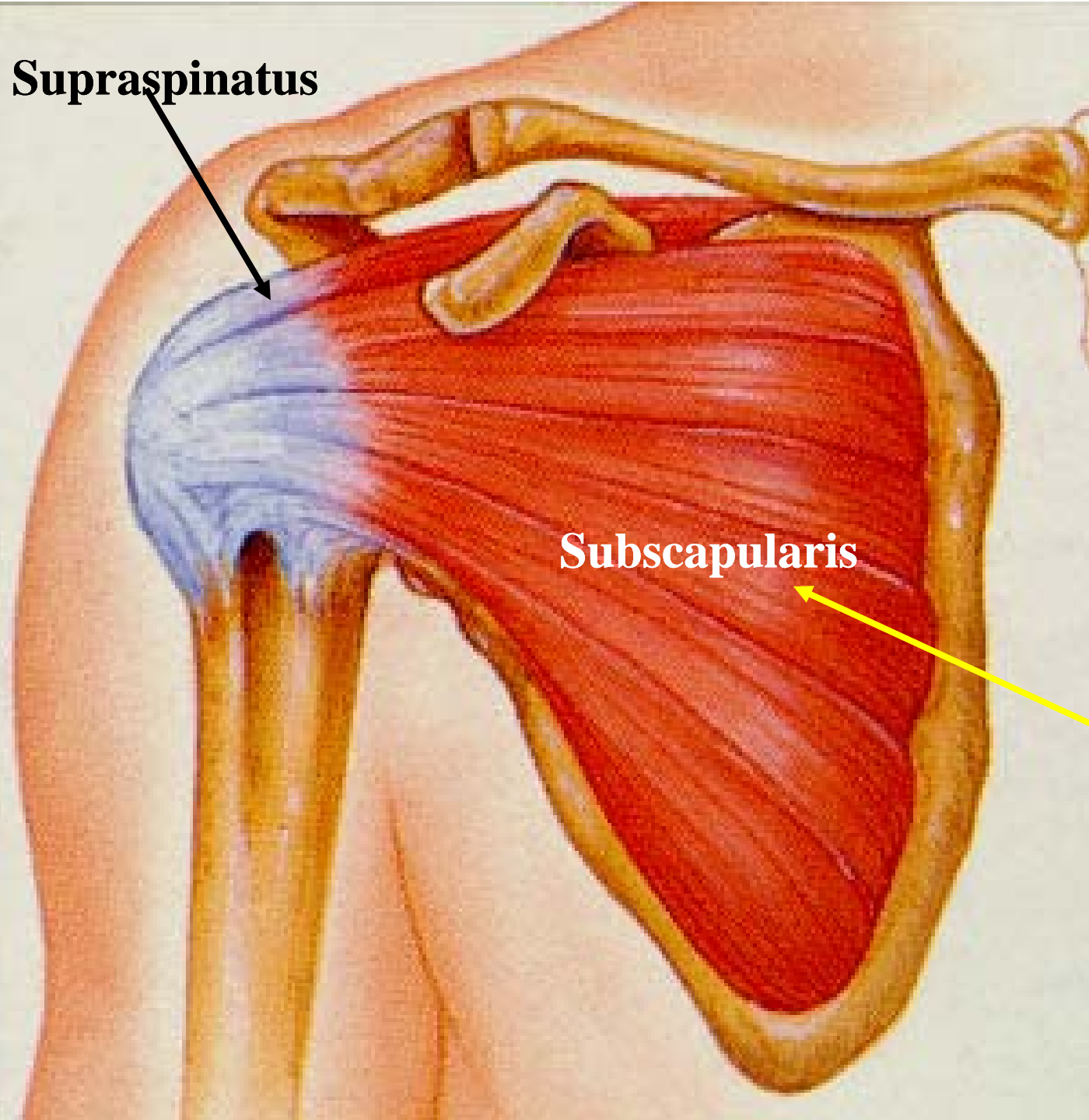
**CORICOCALVICULAR
LIGAMENT**

**ACROMIO-
CLAVICULAR
LIGAMENT**

**CORACO-
ACROMIAL
LIGAMENT**

**CAPSULAR
LIGAMENTS**



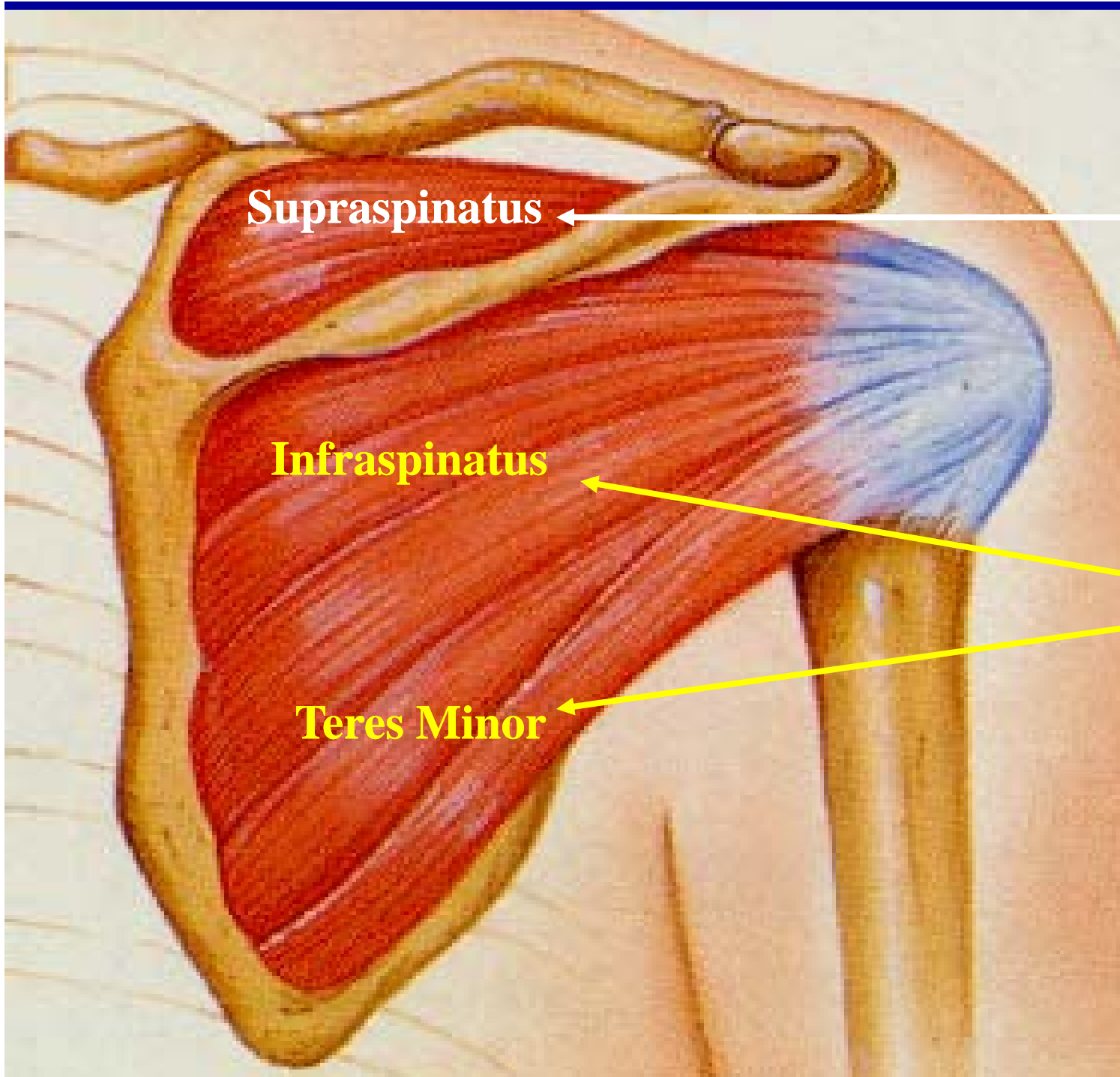


Supraspinatus

Subscapularis

**Rotator
Cuff
Muscles**

*Internal
Rotator*

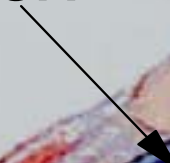


Abduction

**First 90
Degrees**

**External
Rotation**

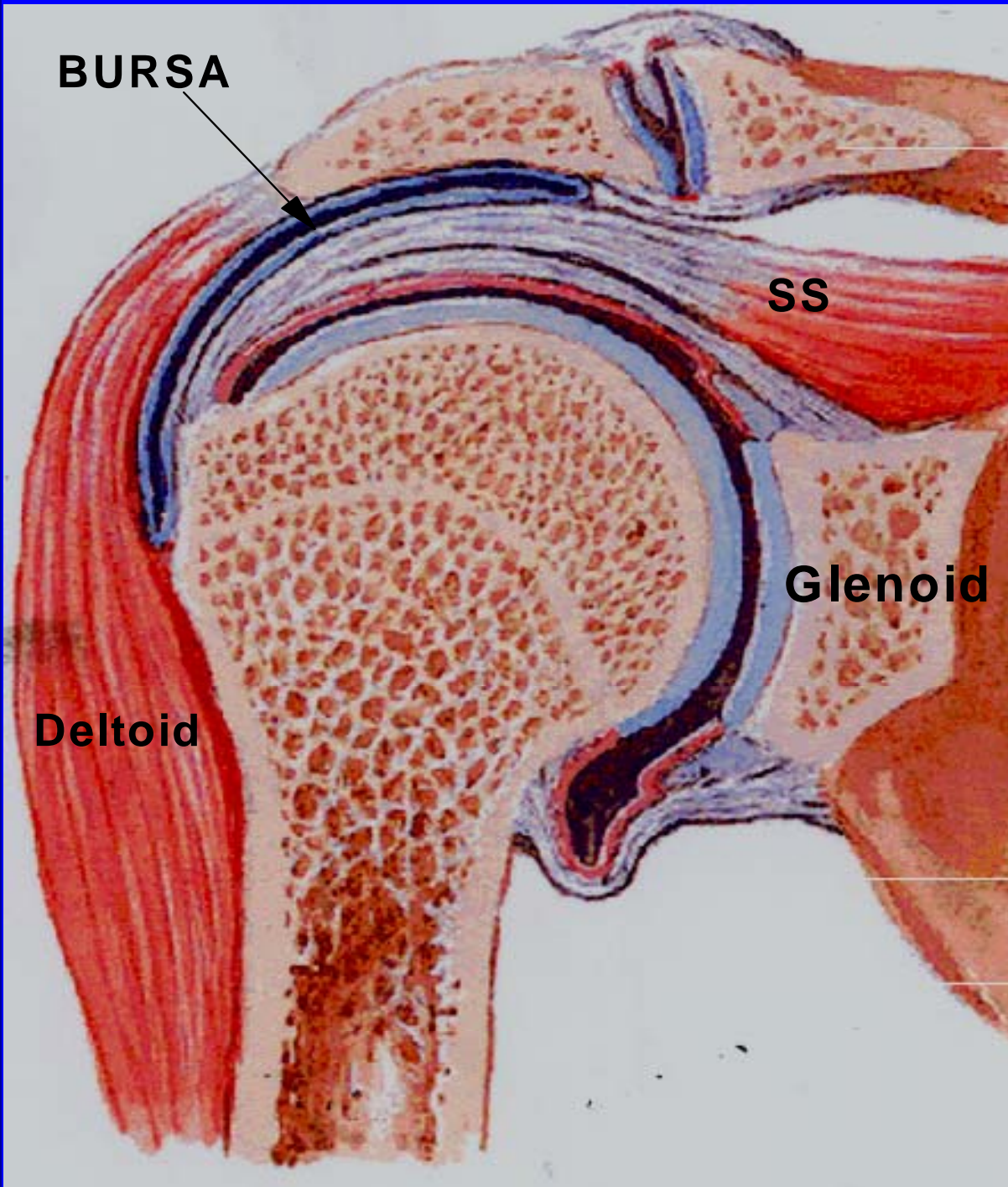
BURSA



SS

Glenoid

Deltoid

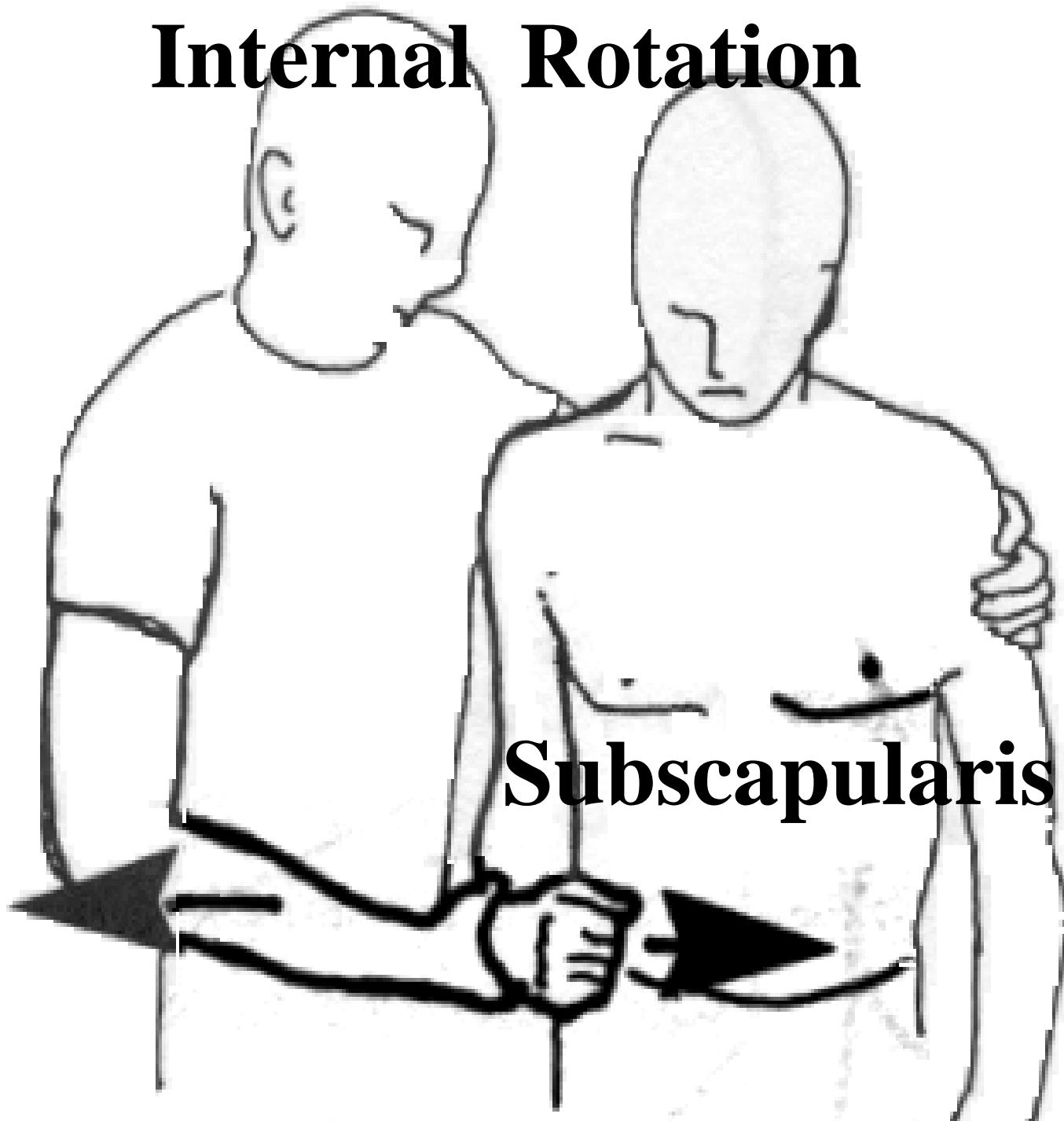


Why did God make
the Shoulder Joint
more moveable than
the Hip Joint in
Physicians?

Case 1

- **Right Shoulder pain off and on the past 4 years, worse the past 2 weeks, awakens him at night**
- **Has problems with combing his hair and putting on his shirt, cannot do overhead stroke with tennis**
- **Exam- weak external rotation, empty can test pain and weakness on the right**
- **Positive Neer, Hawkins and "bye bye" tests**

Internal Rotation



Subscapularis



The diagram shows two figures illustrating the external rotation of the shoulder. The figure on the left is shown from the side, with the right arm extended forward. A black arrow points from the elbow towards the right, indicating the direction of external rotation. The figure on the right is shown from the front, with the right arm extended forward. A black arrow points from the elbow towards the left, indicating the direction of external rotation. The text 'External Rotation' is centered between the two figures. At the bottom, the text 'Infraspinatus' is on the left and 'Teres Minor' is on the right, with a horizontal line connecting them.

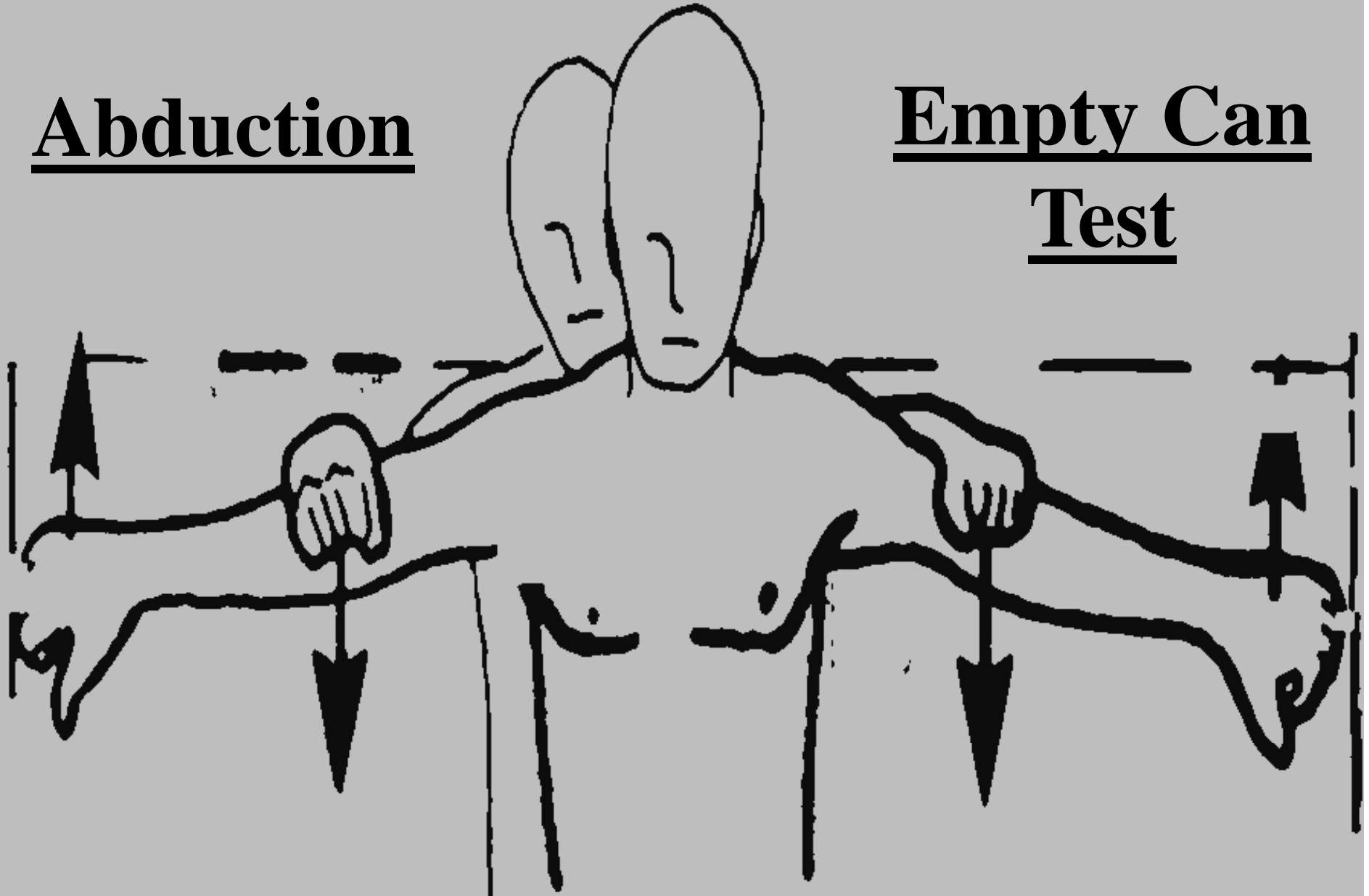
External Rotation

Infraspinatus

Teres Minor

Abduction

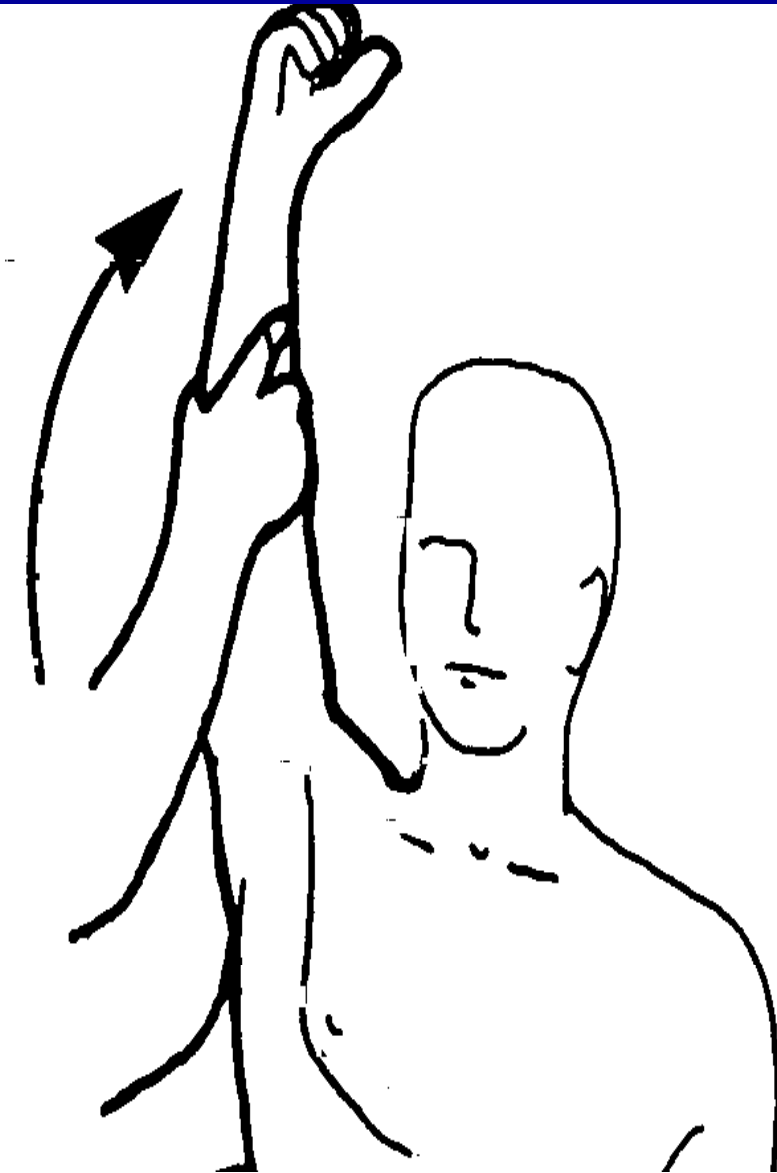
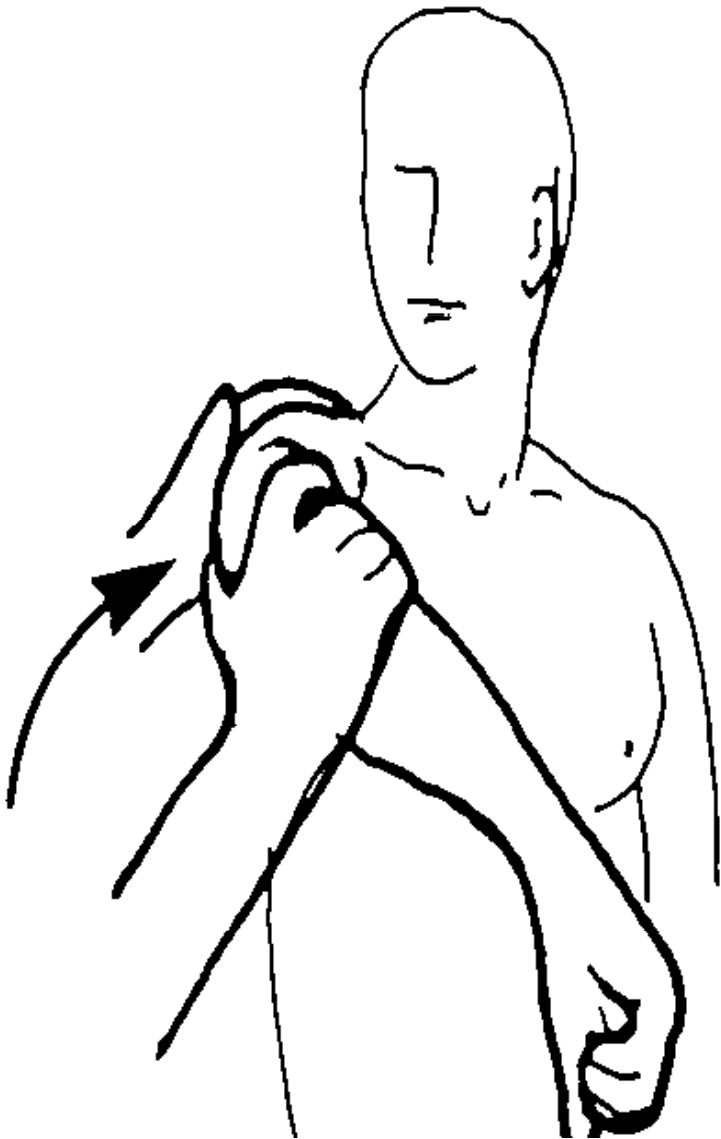
Empty Can
Test

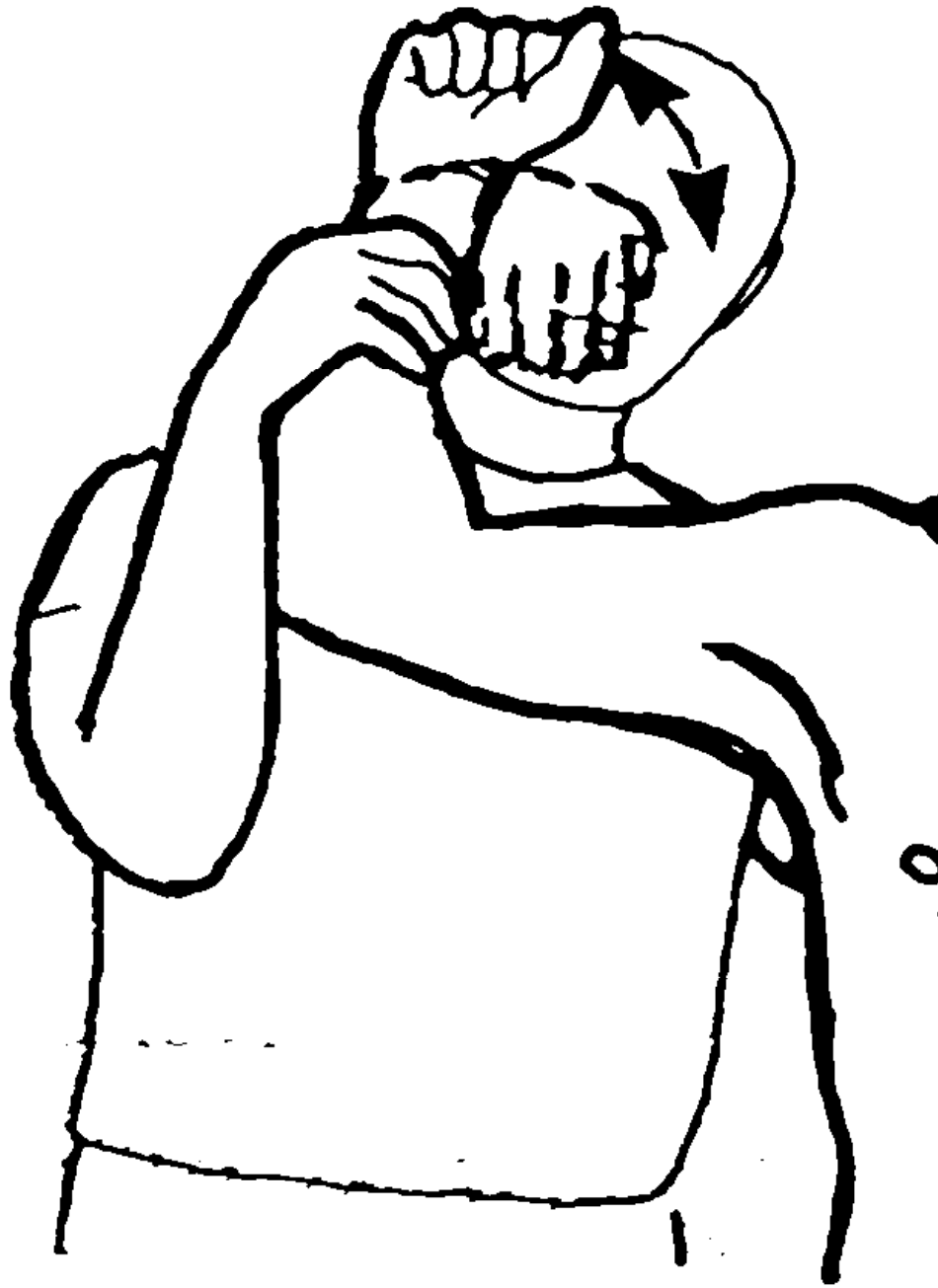

Supraspinatus

Hawkins

Neer





**Anterior
Subluxation+
impingement
Bye-Bye test**

Inspection

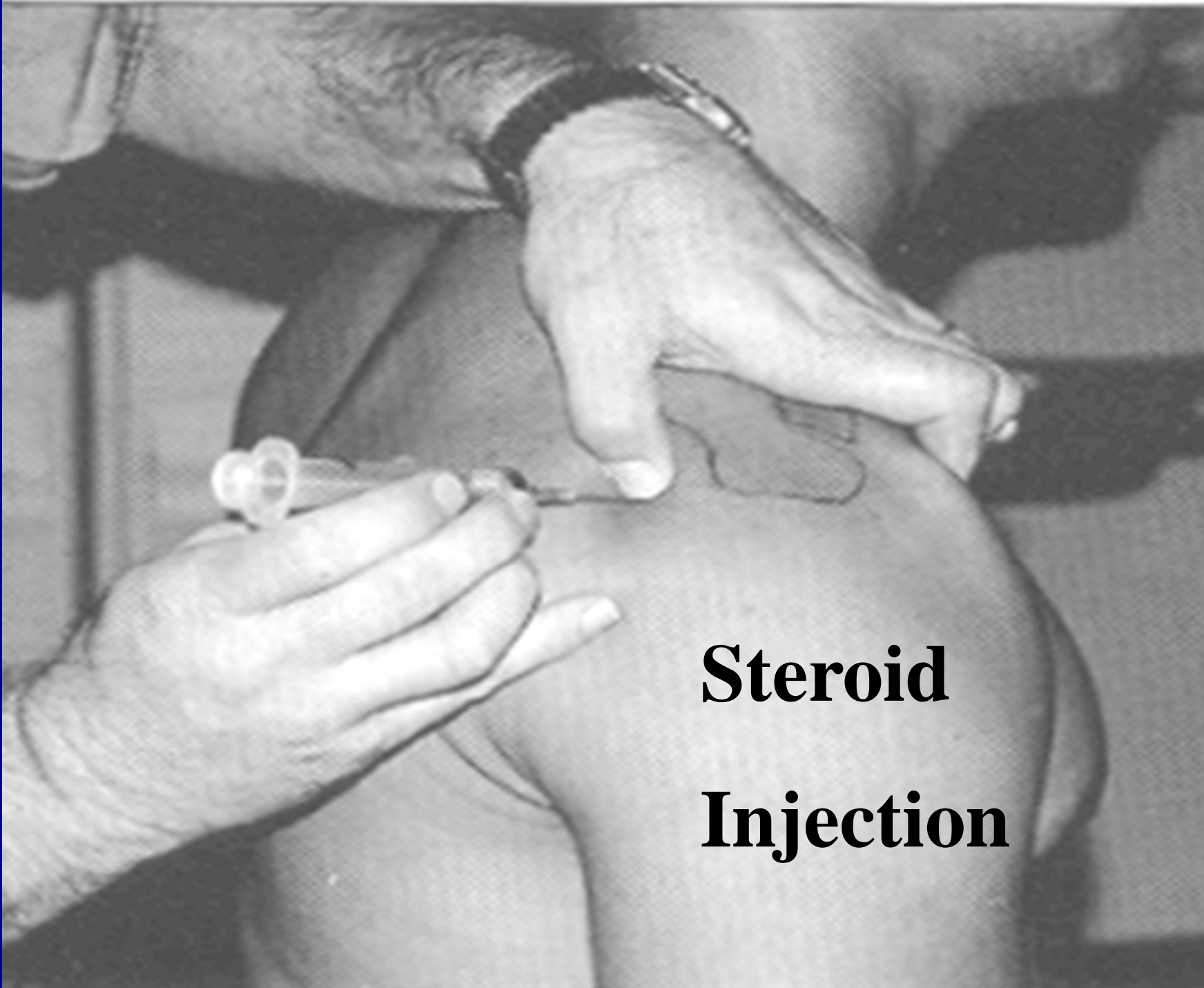


Impingement Syndrome

- **Most common cause of shoulder pain in primary care**
- **Includes rotator cuff tear (partial or complete), cuff Tendonitis and sub-acromial bursitis.**
- **With arm raised supraspinatus tendon is compressed under the coraco-acromial ligament**
- **Degeneration, Tendonitis lead to weakness, instability and subluxation.**

Treatment of Impingement

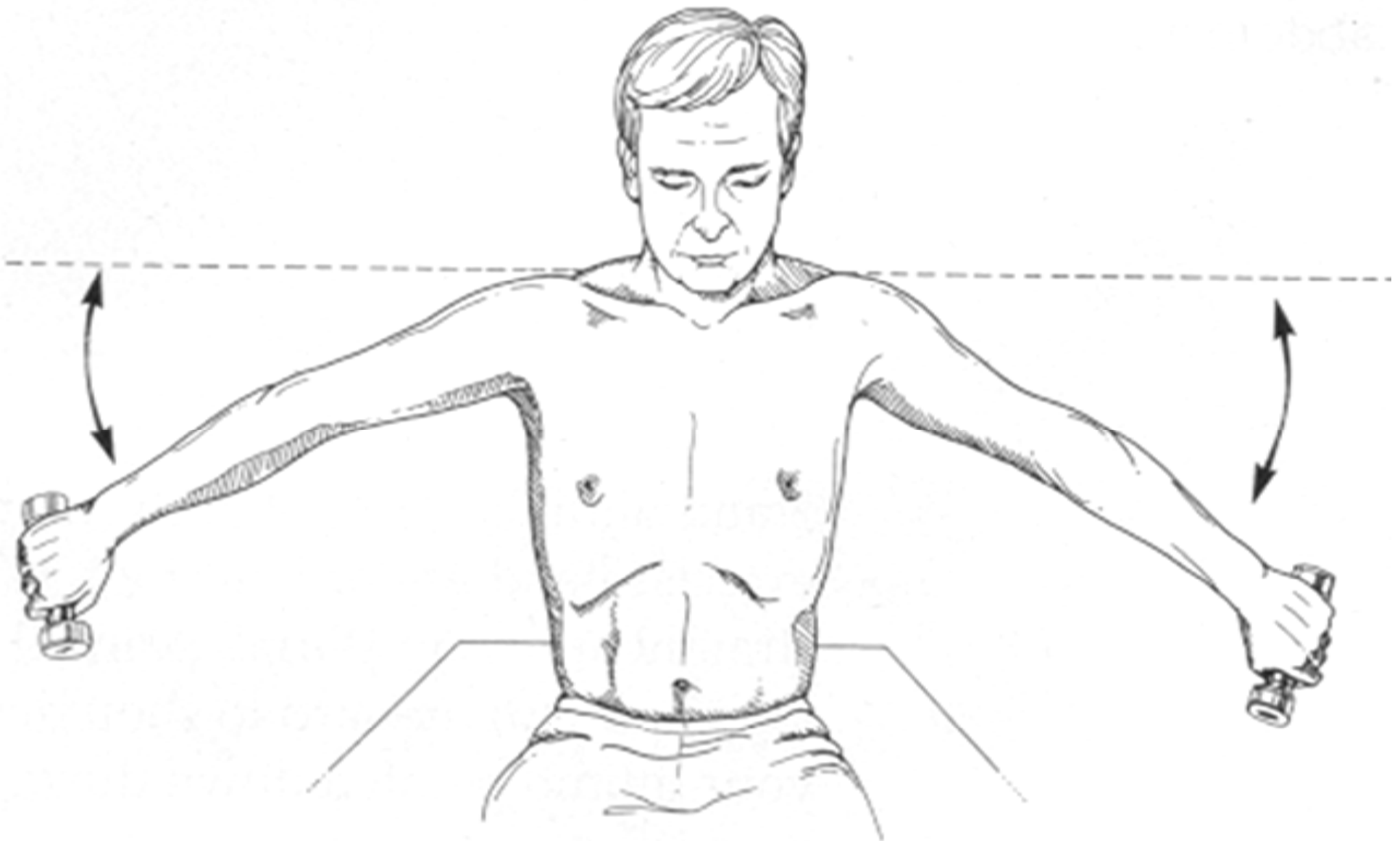
- **NSAIDS (with caution)**
- **Short period of rest but be careful with slings**
- **Caution with the words "take it easy" frozen shoulder??**
- **Reduce offending activities-**
- **Ice cup massage**
- **EXERCISES-EXERCISES-EXERCISES**
- **Steroid Injections and Surgery if all else fails**



**Steroid
Injection**

Rehabilitation Exercises

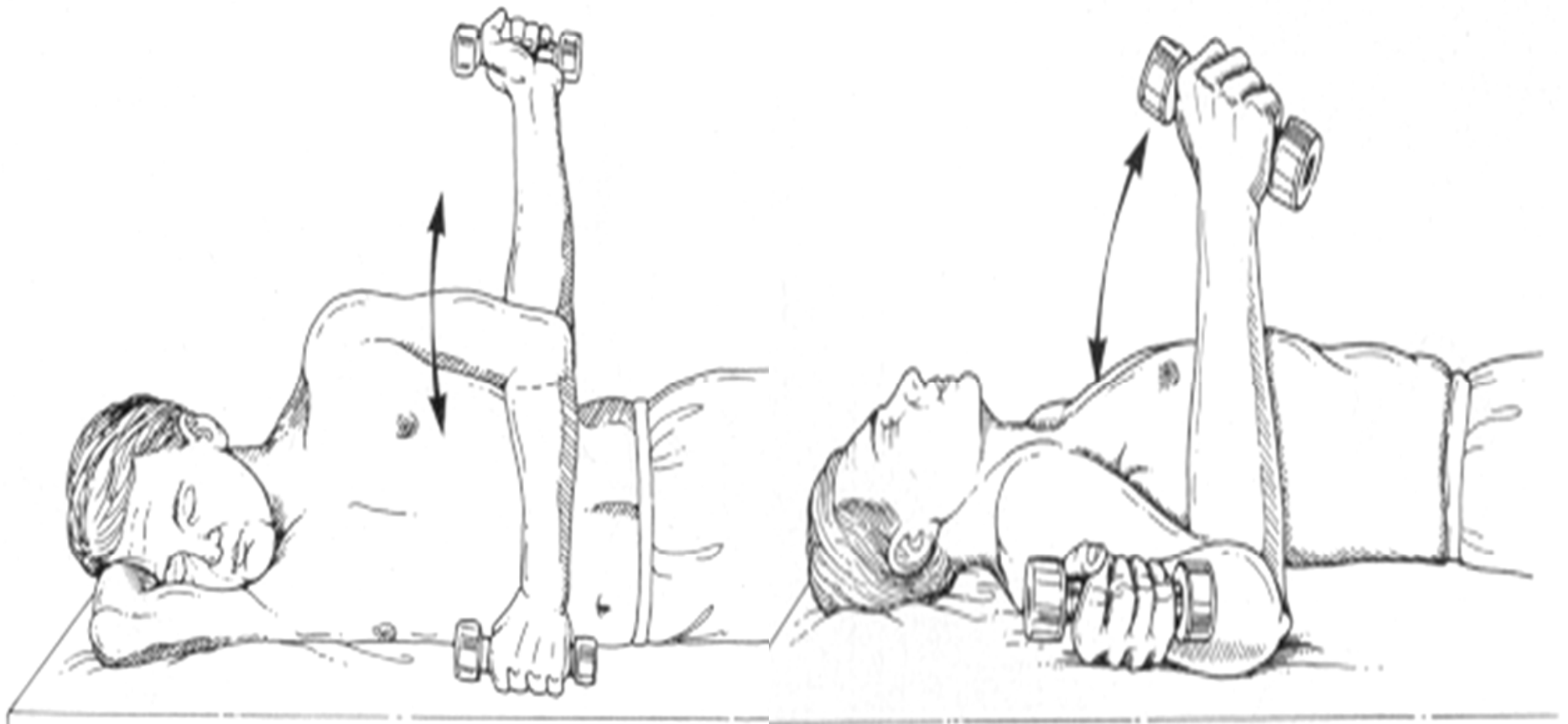
Supraspinatus Exercise



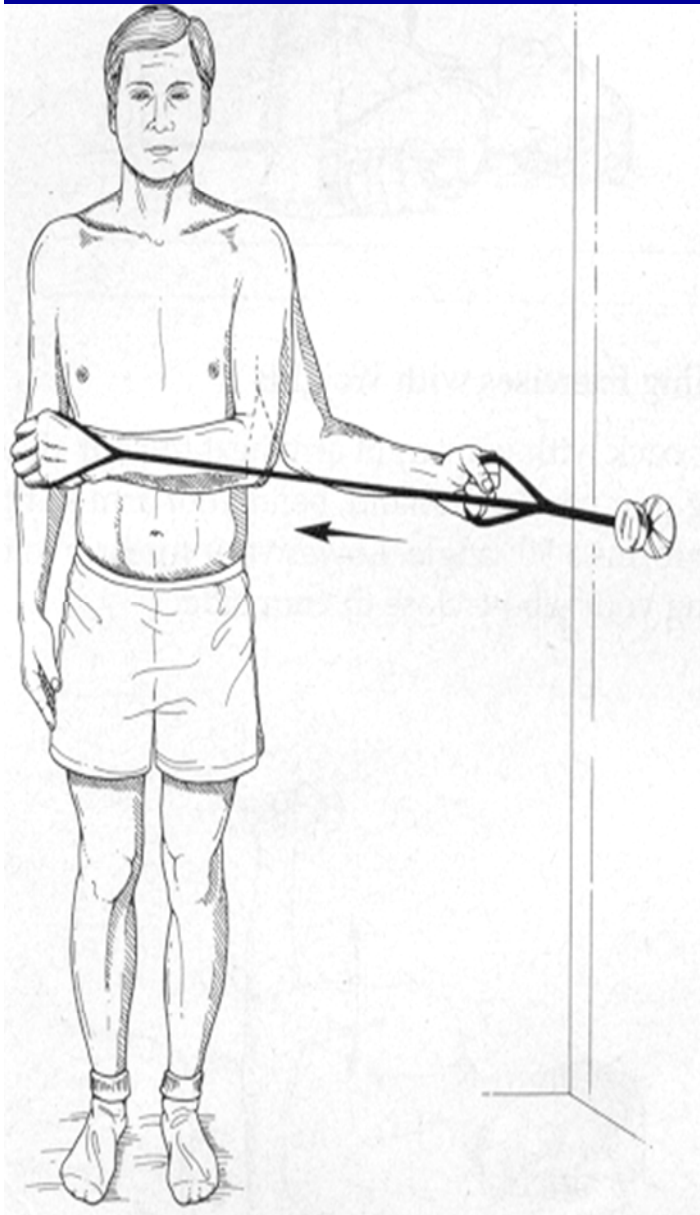
**External
Rotation**

**Internal
Rotation**

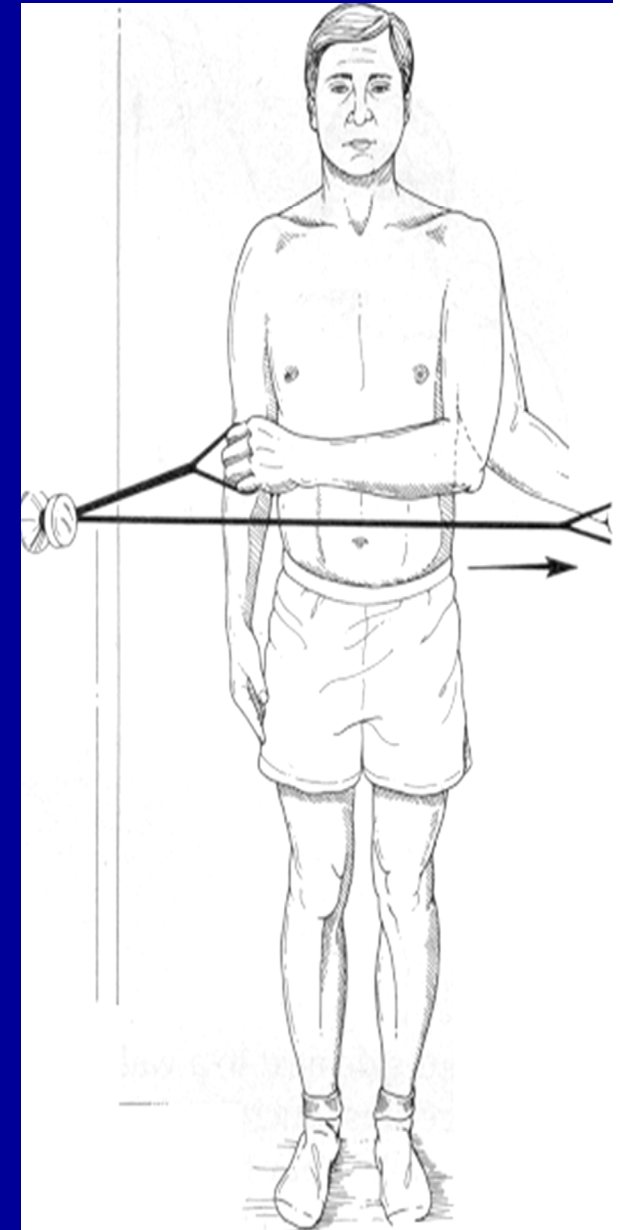
Exercises



Internal Rotation



External Rotation



Exercises